

Case Report

A case of thrombectomy of a large volume thrombus in the ICA



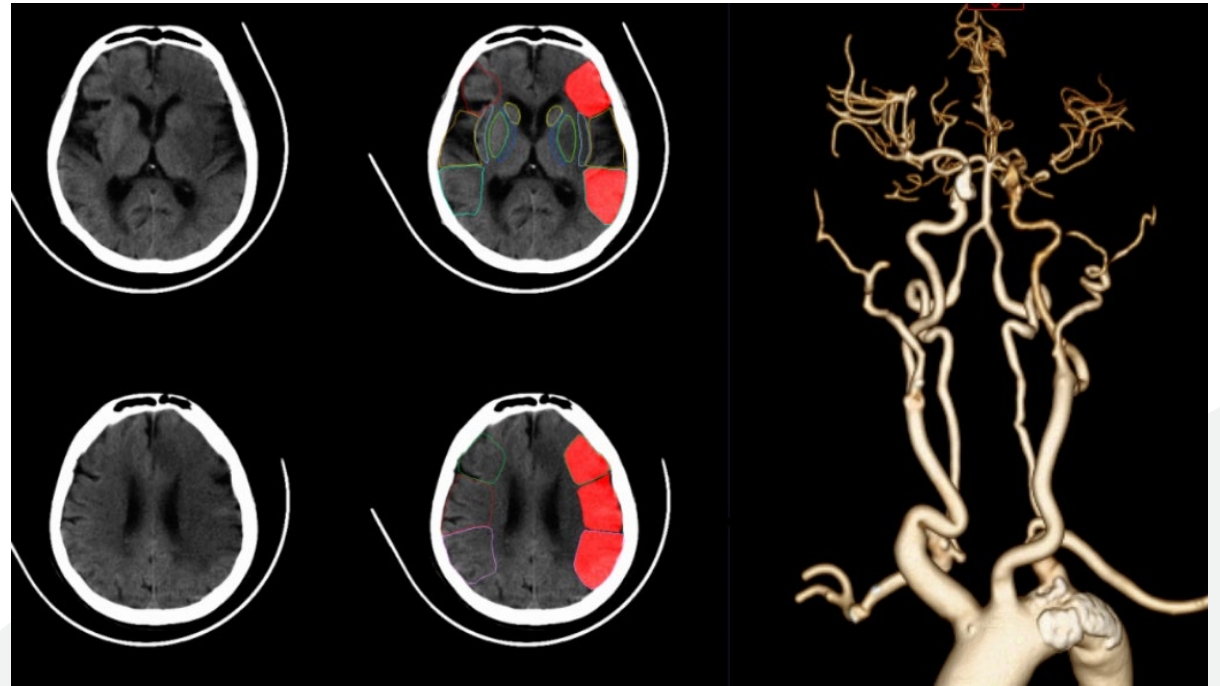
Patient information

- Male, 57 years old
- Unconscious for 6 hours
- NIHSS score: 22
- GCS score: 9

*Courtesy of:
Haiyun Chen, Sanya Center Hospital*

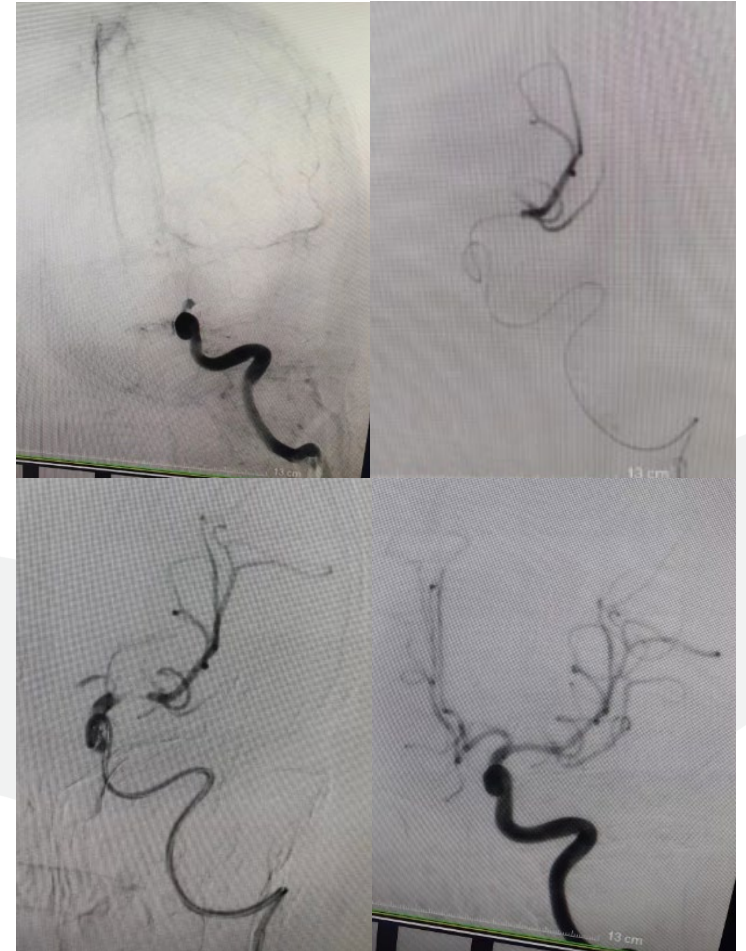Preoperative Examination

- Cerebral Infarction
- Left internal carotid artery occlusion



Procedure

- Angiography indicated occlusion of the end of the ICA
- Microguidewire and microcatheter passed through the occluded segment to the M2 segment with imaging that indicated a normal distal vessel
- 6mm x 30mm Thrombrite Clot Retriever Device in place and released
- With a 6F 125cm Cylone Aspiration Catheter pull-out for one-time recanalization



Postoperative Angiography

- NIHSS score at 24 hours postoperatively: 16
- NIHSS score at 1 week postoperatively: 12, mRS: grade 4

