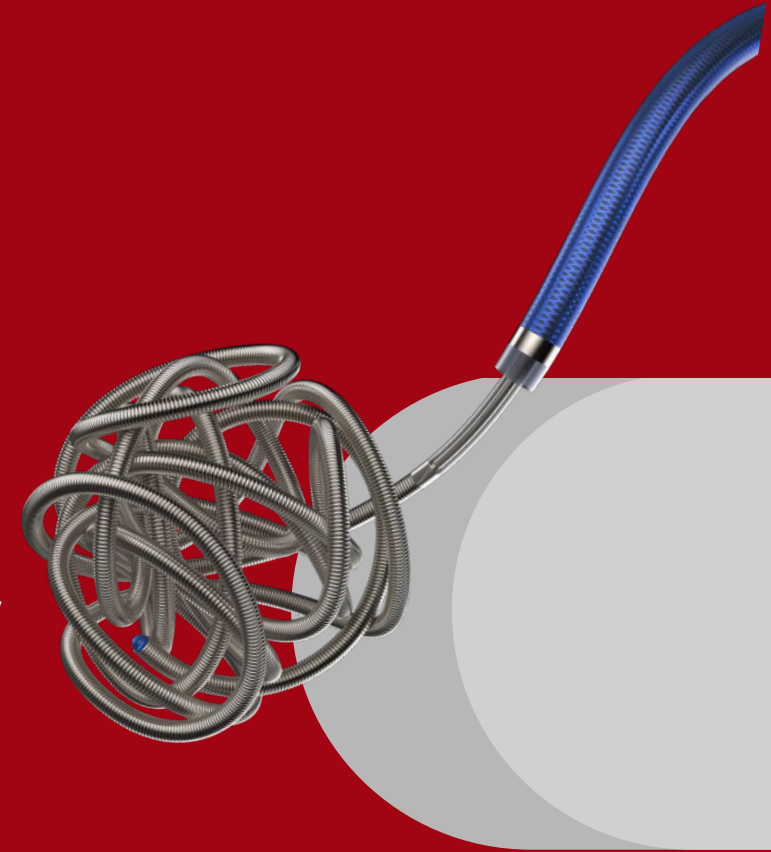




TONBRIDGE
MEDICAL

Case Report

**Embolization of Posterior Communicating Artery
Aneurysm in the Right Internal Carotid Artery**



Patient information

- Female, 69 years old.
- The patient presented with a sudden headache approximately 4 days ago. Intracranial CT revealed subarachnoid hemorrhage.
- GCS score: 15 points.
- mRS score: 1 point.
- Hunt-Hess grading: Grade I.

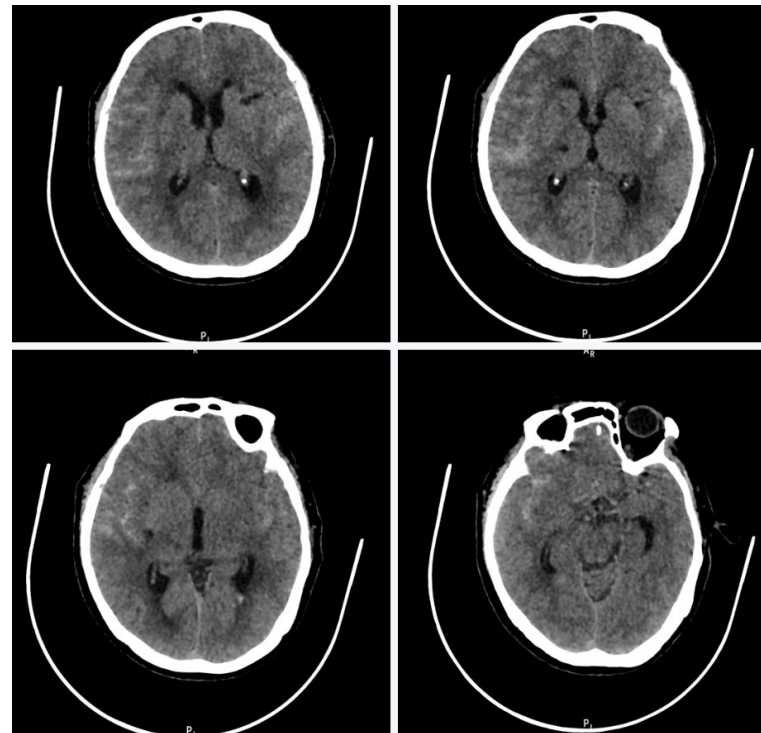
Courtesy of:

Jie Shen, MD, Qilu Hospital of Shandong University

Dr. Jinchun Chi and Dr. Pengchang Zhang, Linqing People's Hospital

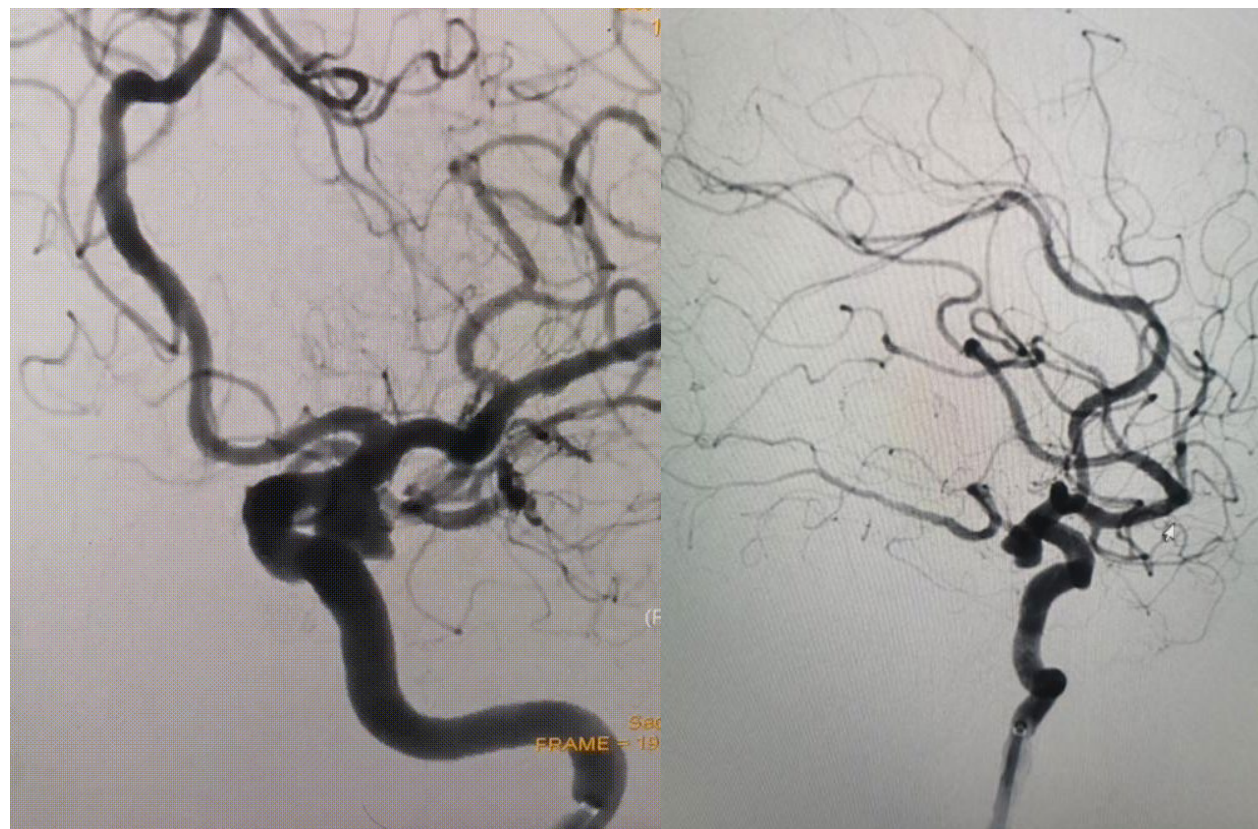
Preoperative Examination

- Preoperative CT: Bilateral lateral sulci and partial intracranial fissures show high-density shadows.



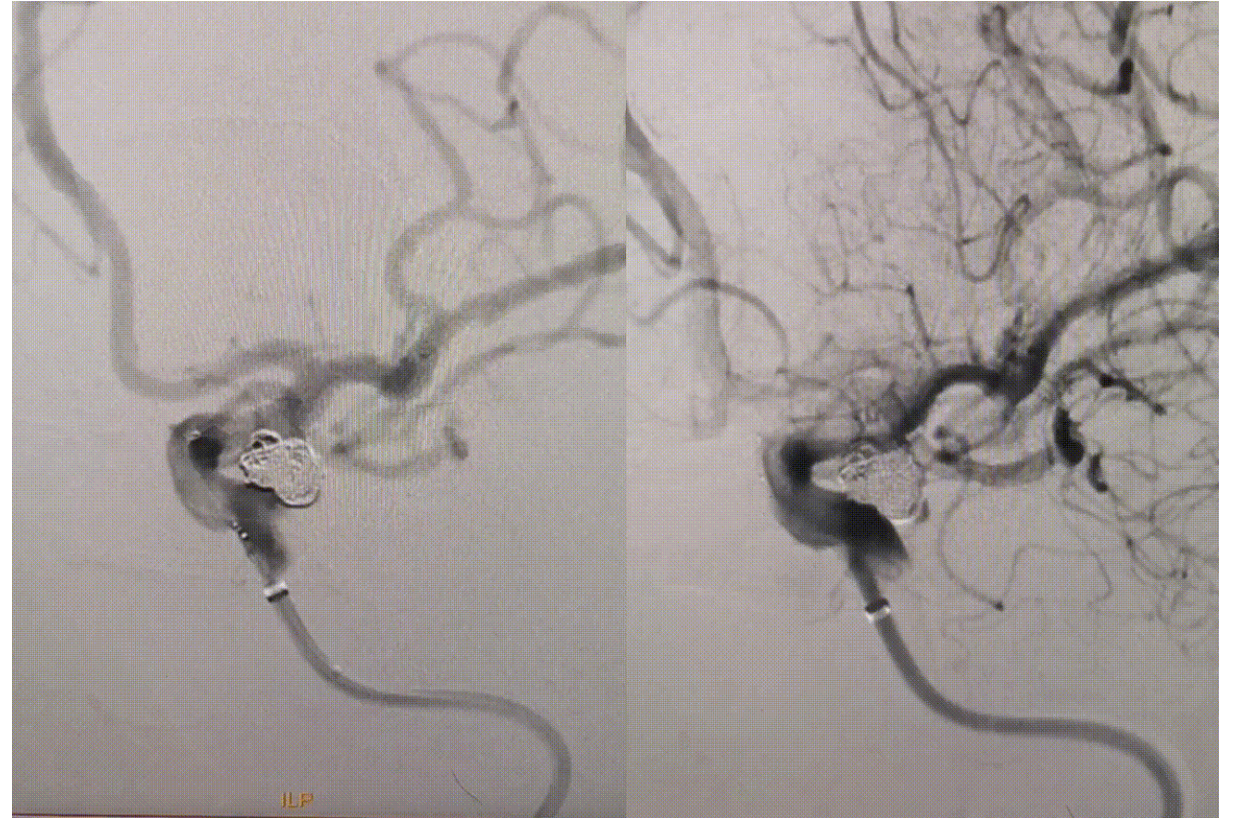
Preoperative Examination

- DSA: In the right internal carotid artery, a saccular aneurysm is observed in the communicating segment.
- The neck of the aneurysm measures approximately 4.3mm, and the size of the aneurysm body is approximately 7.9mm x 6.9mm.



Procedure

- Using an LVIS 4.0mm*22mm stent, semi-deployment is performed. Subsequently, a 6mm*20cm GEKKO coil and a 5mm*15cm GEKKO coil are sequentially introduced, achieving framing on angiography.
- Continuing the procedure, additional GEKKO coils are deployed: 4mm*12cm, 4mm*6cm, 3mm*8cm, 3mm*6cm, 2mm*6cm.



Postoperative Angiography

- The coil packing within the aneurysm sac is densely filled, indicating successful embolization.

