



**TONBRIDGE
MEDICAL**

Case Report

**Acute Occlusion of the Right Internal Carotid
Artery with Progressive Cerebral Infarction**



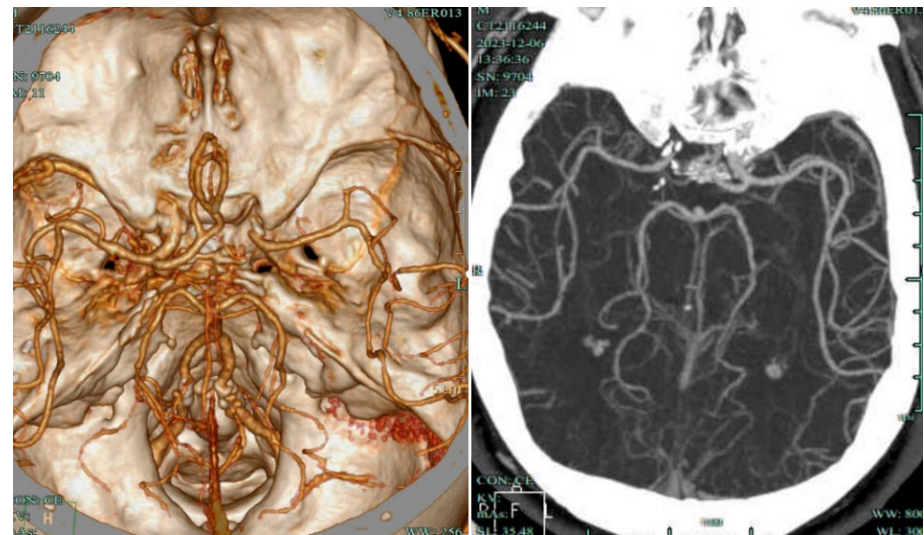
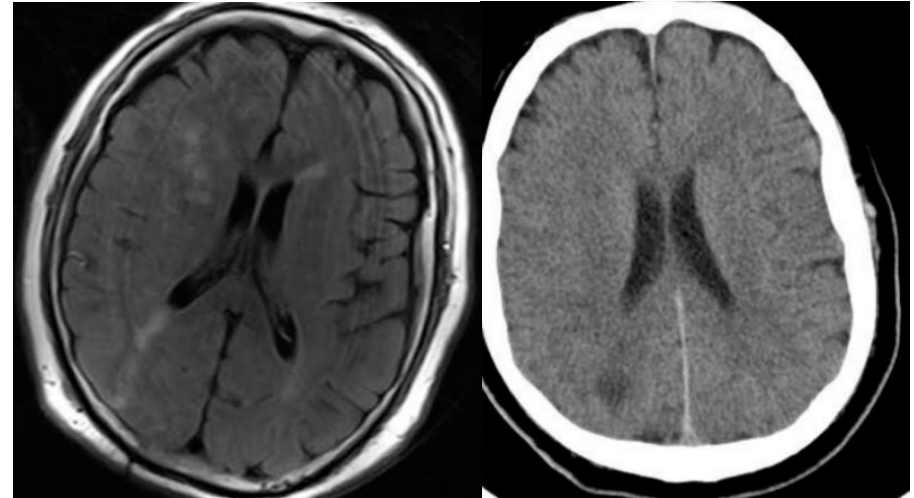
Patient information

- Male, 52 years old
- Slurred speech with unstable walking for 4 hours

*Courtesy of:
Simin Peng, Xinchang People's Hospital*

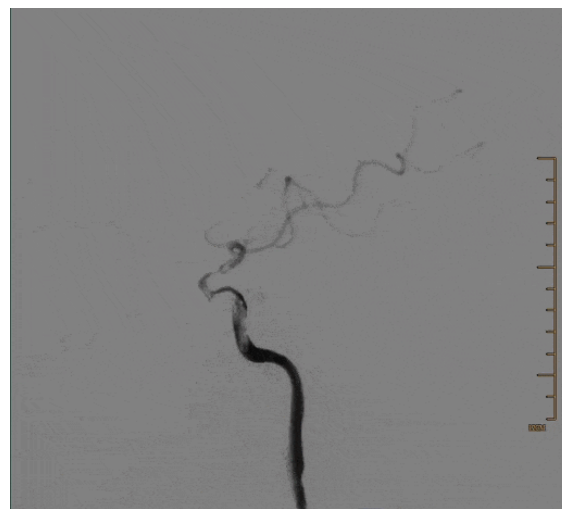
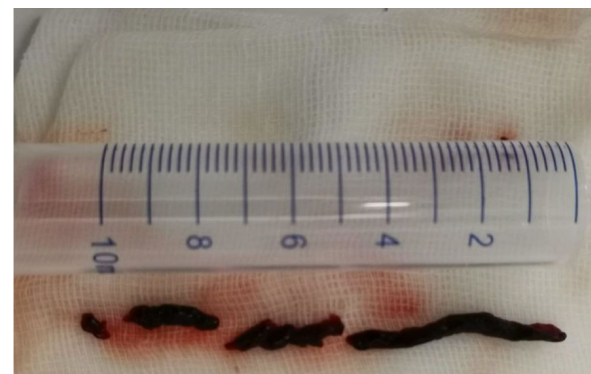
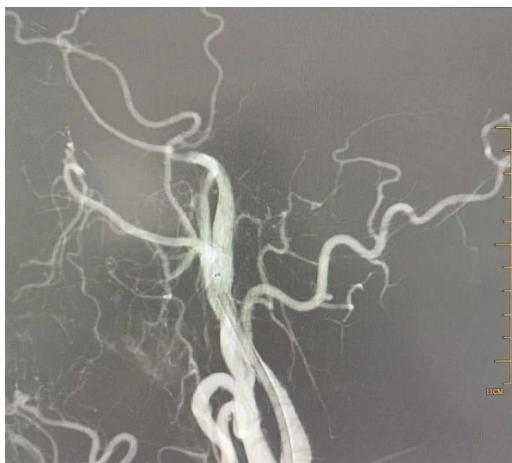
Preoperative Examination

- Cerebral infarction of the right parieto-occipital lobe, indicating stenosis and occlusion of the large cerebral arteries
- Multiple acute cerebral infarcts in the right cerebral hemisphere
- Occlusion of segment C1-C5 and severe stenosis of segment C6-C7 of the right internal carotid artery



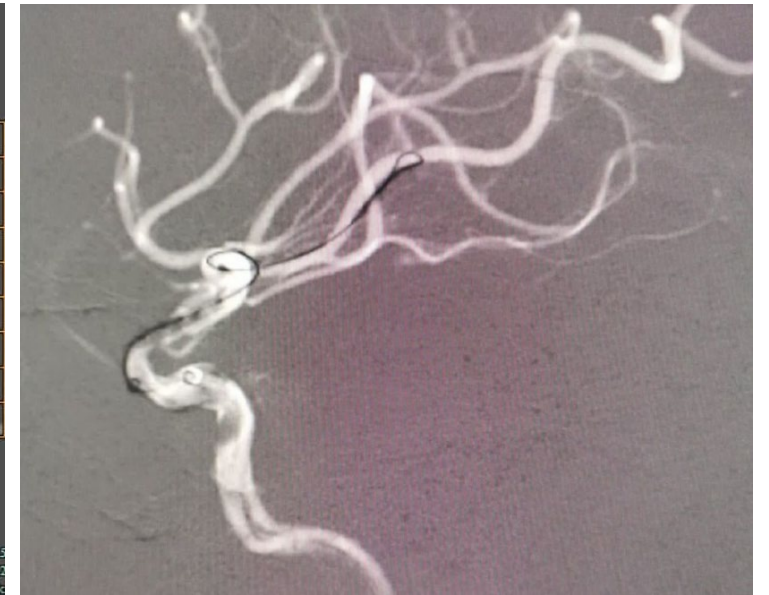
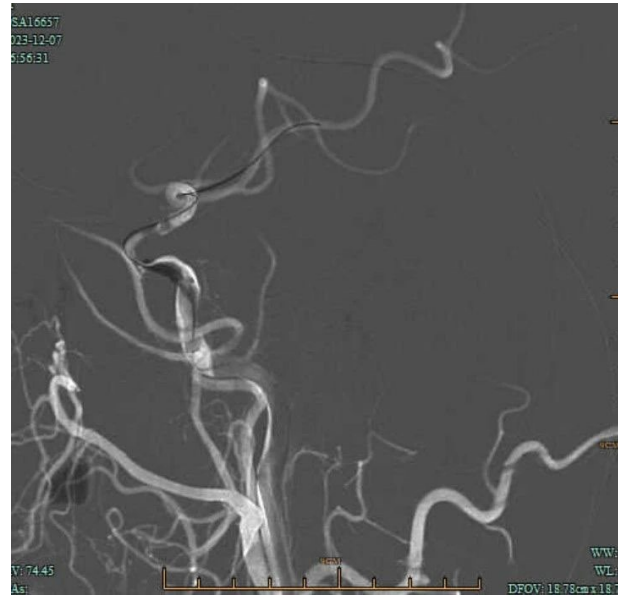
Procedure

- The right internal carotid artery was aspirated with a 6F 115cm Tonbridge Cylone Aspiration Catheter to remove a large amount of thrombus
- After partial recanalization of the right internal carotid artery thrombectomy, the original occlusion site was confirmed to be the C4 segment of the right internal carotid artery, and severe stenosis of the C6 segment was noted



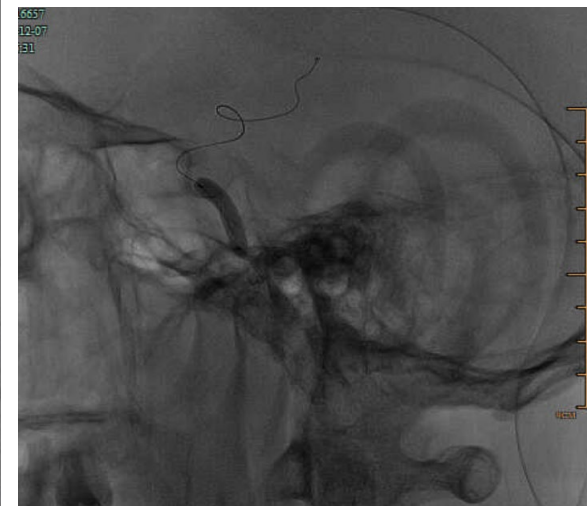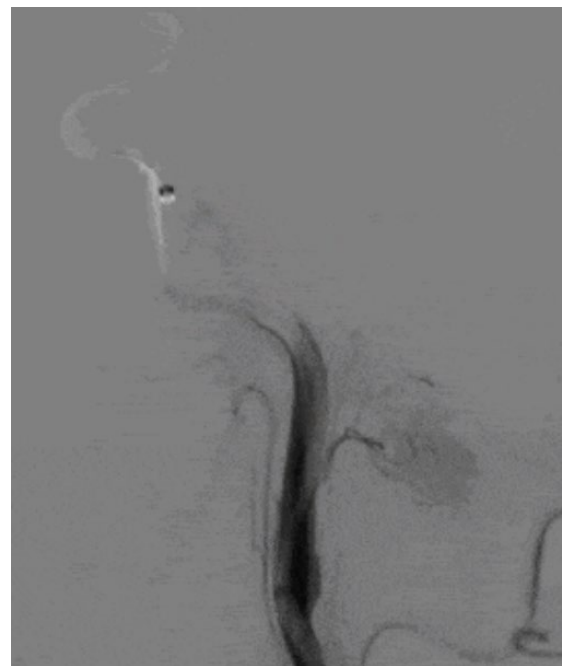
Procedure

- Right internal carotid artery segment C4 was dilated with a Tonbridge Intracranial Balloon Dilatation Catheter 2.0*12mm (8atm pressure)
- Severe stenosis of the C6 segment of the right internal carotid artery, dilated with the Tonbridge Intracranial Balloon dilatation catheter 2.0*12mm (6atm pressure)



Procedure

- Occlusion of segment C4 of the right internal carotid artery, which was still not patent after balloon dilatation, determined further stent placement
- Right internal carotid artery C4 was dilated with a 3.5*15mm stent



Postoperative Angiography

- Recanalization of Right Internal Carotid Artery Occlusion

