




TONBRIDGE
MEDICAL

Case Report

Thrombectomy in a patient with atrial fibrillation
embolization of the MCA



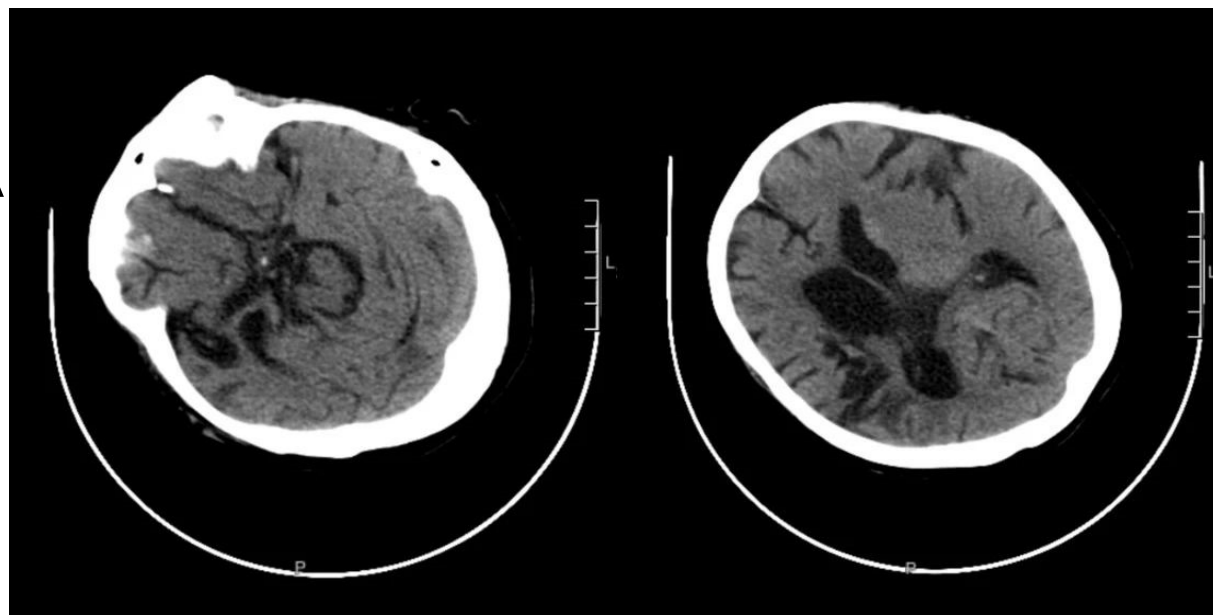
Patient information

- Female, 72 years old.
- History of atrial fibrillation with hyperdense shadow MCA on CT
- GCS score: 4 points
- NIHSS score: 24 points
- mRS score: 5 points

*Courtesy of:
Bo Peng, Dandong City Center Hospital*

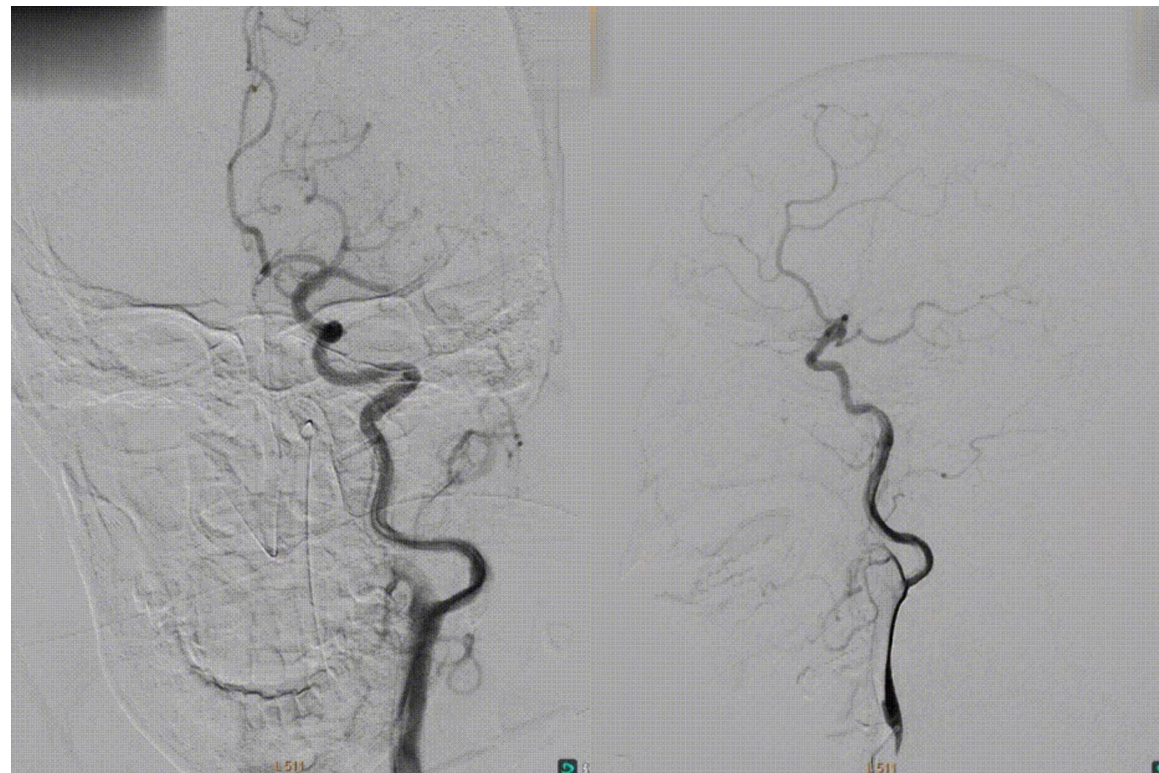
Preoperative Examination

- Acute cerebral infarction
- Severe ischemia of the left MCA
- Atrial fibrillation embolization is highly probable



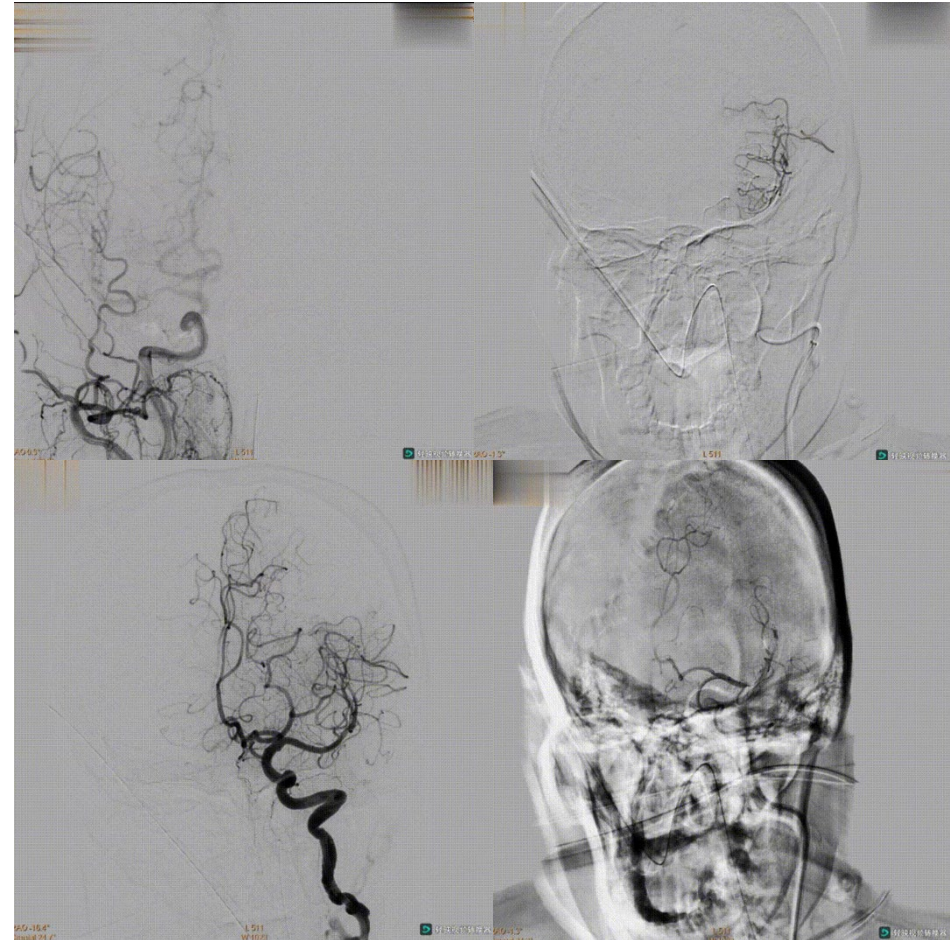
Preoperative Examination

- Lateral angiography shows tortuous ICA with no stenosis at its origin
- MCA with visible rounded segmental dissection, consider embolization



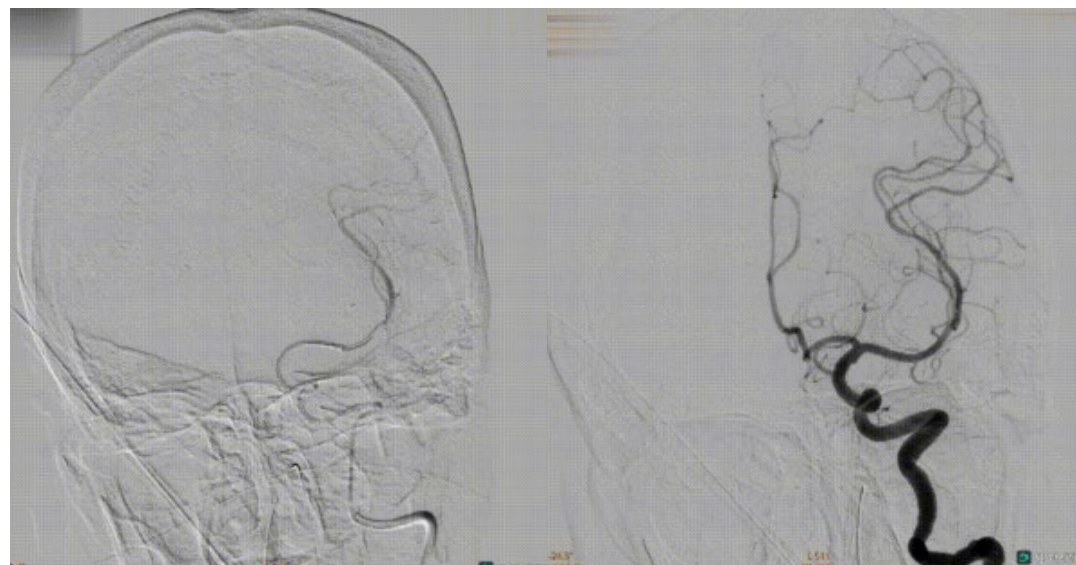
Procedure

- Cylone™ Aspiration Catheter delivered to C4 segment of ICA, microguidewire and microcatheter through occluded segment
- 4×30mm Thrombite™ Clot Retriever Device release with visible in-stent thrombus shadow.



Procedure

- The stent was released in the superior trunk of the MCA and no in-stent thrombus shadow was seen on DSA; thrombus fragmentation was considered and the stent was retrieved
- Repeat angiography, see left MCA recanalization, mTICI grade 2b



Postoperative Angiography

- Lateral angiography of the left MCA

